

VIDEOS IN CLINICAL MEDICINE

## Placement of an Arterial Line

Ken Tegtmeyer, M.D., Glenn Brady, M.D., Susanna Lai, M.P.H.,  
Richard Hodo, and Dana Braner, M.D.

### INDICATIONS

Radial arterial lines are important tools in the treatment of critically ill patients. Continuous monitoring of blood pressure is indicated for patients with hemodynamic instability that requires inotropic or vasopressor medication. An arterial line allows for consistent and continuous monitoring of blood pressure to facilitate the reliable titration of supportive medications. In addition, arterial lines allow for reliable access to the arterial circulation for the measurement of arterial oxygenation and for frequent blood sampling. The placement of arterial lines is an important skill for physicians to master as they treat critically ill patients.

An arterial line is also indicated for patients with significant ventilatory deficits. Measurement of the partial pressures of arterial oxygen and arterial carbon dioxide provides more information about the status of gas exchange than does arterial oxygen saturation.

### CONTRAINDICATIONS

The contraindications to the placement of an arterial line are few but specific. Placement of an arterial line should not compromise the circulation distal to the placement site, which means that sites with known deficiencies in collateral circulation — such as those involved in Raynaud's phenomenon and thromboangiitis obliterans or end arteries such as the brachial artery — should be avoided.

The value of the Allen test, which is used to verify collateral circulation to the hand through alternate occlusion of the radial and ulnar arteries while the hand is checked for perfusion, is somewhat controversial. Some studies have been able to demonstrate adequate perfusion with the use of other techniques that contradict the results of the Allen test.<sup>1,2</sup> Other contraindications include infection of the site where the catheter is to be placed and traumatic injury proximal to the proposed insertion site.

### PREPARATION

There are several techniques for the placement of a radial arterial line; two of the more common are known as “over the wire” and “over the needle.” A modified Seldinger technique can also be used but is not described in this video.

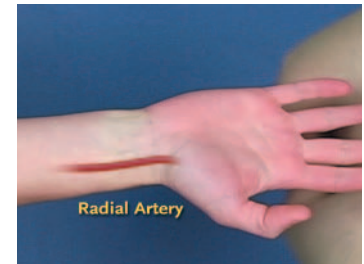Preparation for both techniques is identical. The equipment needed includes a sterile preparation solution and a sterile field, a board and tape to secure and position the wrist, 1 percent lidocaine solution (without epinephrine) and a small-gauge needle and syringe for delivery, an angiographic catheter and needle, a wire if the over-the-wire technique is to be used, material such as suture or tape to secure the line once it has been placed, and a transduction system for monitoring.

After the risks of the procedure have been appropriately assessed and consent has been obtained from the patient, the hand should be positioned on the wrist board. The hand should be placed in moderate dorsiflexion, which brings the artery

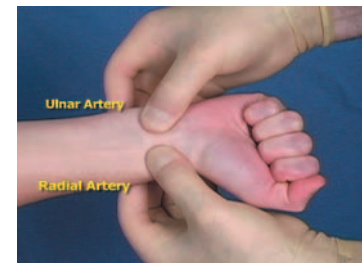From the Departments of Medical Informatics and Clinical Epidemiology and Pediatrics, Oregon Health and Sciences University, Portland, Ore. Address reprint requests to Dr. Braner at 3181 S.W. Sam Jackson Park Rd., Portland, OR 97239-3098, or at branerd@ohsu.edu.

N Engl J Med 2006;354:e13.

Copyright © 2006 Massachusetts Medical Society.



Location of the radial artery.



Performance of the Allen test.

closer to the skin and aids successful placement of the line. A flexible board or roll placed under the wrist can ease positioning. The site should be cleaned with a sterile preparation solution and draped appropriately. Sterile gloves should be used for catheter placement.

#### PLACEMENT OF THE LINE

The radial artery is palpated 1 to 2 cm from the wrist, between the bony head of the distal radius and the flexor carpi radialis tendon. In a conscious patient, lidocaine may be infused at the insertion site to help minimize pain on insertion of the line.

For the over-the-wire technique, the artery should be palpated gently with the nondominant hand proximal to the insertion site. The needle should enter at a 30-to-45-degree angle to the skin directly over the point at which the pulse is palpated. The catheter should be advanced slowly through the artery; once a flash of blood is seen in the hub of the catheter, the needle should be advanced a few millimeters farther through the vessel. The wire should be prepared and the needle slowly withdrawn until pulsatile blood flow is observed. At this point, the wire is advanced into the vessel. The wire should thread easily and without resistance. Once the wire is in the vessel, the needle can be removed; the catheter is then advanced over the wire. Pressure should be placed over the artery proximal to the catheter, the wire removed, and the catheter connected to a transduction system.


For the over-the-needle technique, the initial approach is the same. The pulse should be palpated proximal to the insertion site; the needle should penetrate the skin at a 30-to-45-degree angle directly over the palpated pulse and then be advanced slowly toward the pulse. Once pulsatile blood return is seen in the catheter, the catheter should be advanced slightly farther to ensure that the catheter itself is within the vessel. The catheter angle should then be lowered to 10 to 15 degrees and the catheter advanced over the needle into the vessel.

Regardless of technique, the catheter should be secured in place. Suturing is the preferred method, but many practitioners choose to tape the catheter securely in place. It is important to ensure that the catheter is not subject to tension from the tubing or at risk of being removed by the patient.


Perfusion to the hand should be reassessed after placement of the arterial line and at frequent intervals while the line is in use. Any sign of vascular compromise at any time should prompt the removal of the line. The line should be removed as early as possible after it is no longer needed.

#### COMPLICATIONS

Arterial spasm and an inability on the part of the clinician to pass the wire or catheter through the artery are the most common difficulties in catheterization. If spasm is suspected, attempts at catheterizing that artery should be abandoned and an alternative site selected. If the wire or catheter cannot be passed despite the return of pulsatile blood, this is either because the angle of the needle in relation to the vessel is too acute or because the needle tip is not completely within the artery. With adjustment of the angle, a slight advance, or withdrawal of the needle, placement may yet be successful.



Entry of over-the-wire technique.



Over-the-needle technique.

#### REFERENCES

1. Abu-Omar Y, Mussa S, Anastasiadis K, Steel S, Hands L, Taggart DP. Duplex ultrasonography predicts safety of radial artery harvest in the presence of an abnormal Allen test. *Ann Thorac Surg* 2004; 77:116-9.
2. Fuhrman TM, Pippin WD, Talmage LA, Reilley TE. Evaluation of collateral circulation of the hand. *J Clin Monit* 1992; 8:28-32.

Copyright © 2006 Massachusetts Medical Society.